



## BRIEF REPORT

# VON ZUMBUSCH PSORIASIS: A BRIEF REPORT

André Nazário de Oliveira<sup>1,2\*</sup> | Rodolfo Borges Franco de Macêdo<sup>1</sup> | Sandra Maíra Carrijo Marques Palma<sup>1</sup> | Raquel Marques Sandri<sup>1</sup> | Cristhenise Ragnini Silva<sup>2</sup> | cristhiany Ragnini Oliveira<sup>1,2</sup> | Kelli Fabiane Moreira<sup>3</sup> | Lucas Chiarato Fernandes<sup>2</sup> | Wulagner Farias<sup>1</sup> | Eliane Costa de Oliveira Coelho<sup>1</sup> | Mahler Giordani Mileo<sup>1</sup> | Guilherme Eler de Almeida<sup>1,2</sup> | Rafael Cavatti<sup>1,2</sup> | Flávio de Jesus Junior<sup>1</sup> | Ketlin Batista Morais Mendes<sup>4</sup>

<sup>1</sup>Medical Residency Program – Internal Medicine/Regional Hospital of Cacoal-Rondônia

<sup>2</sup>UNIFACIMED - Faculty of Biomedical Sciences of Cacoal-

<sup>3</sup>Laboranalises - Clinical Laboratory

<sup>4</sup>Medical Residency Program in Gastroenterology – Getúlio Vargas University Hospital/Manaus-Amazonas

## Abstract

Psoriasis is a chronic non-contagious inflammatory disease present in up to 3% of the population. As for the forms of presentation, it can be classified into: vulgar or in plaques (most common manifestation), in drops or gutta, erythrodermic, pustular or arthropathic. Moreover, some atypical cases stand out, such as acute pustular psoriasis namely Von Zumbusch. Systemic complications, such as heart failure and diseases, can be fatal. Next, we report the case of a patient with Von Zumbusch's pustular psoriasis admitted to our service and admitted for clinical investigation.

Keywords: Von Zumbusch, Psoriasis, Pustular Psoriasis

## 1 | INTRODUCTION

Psoriasis is a chronic non-contagious inflammatory disease present in up to 3% of the population. Its origin remains unknown, however it is known to be related to immunological factors, external irritants, diseases and genetic susceptibility (1). The prevalence is evenly distributed between genders. The most prevalent age varies according to the literature, but it is usually present in two peaks. The first one occurring in the third decade of life and the second one around the fifth decade. As for the forms of presentation, it can be classified into: vulgar or in plaques (most common manifestation), in drops or gutta, erythrodermic, pustular or arthropathic (2). Moreover, some atypical cases stand out, such as

acute pustular psoriasis namely Von Zumbusch, a rare form of psoriasis, severe and characterized by numerous small, sterile pustules on an erythematous surface, which agglutinate in purulent areas (3, 4) in which they develop into large areas superficial flaking. Nail bed, palmar and plantar regions are

**Supplementary information** The online version of this article (<https://doi.org/10.15520/arjmcs.v7i03.263>) contains supplementary material, which is available to authorized users.

**Corresponding Author:** André Nazário de Oliveira  
Medical Residency Program – Internal Medicine/Regional Hospital of Cacoal-Rondônia  
Email: [andrenazario\(at\)hotmail.com](mailto:andrenazario(at)hotmail.com)

usually involved. Fever and arthropathies may be present, in addition to hypocalcemia, leukocytosis and elevated laboratory markers of inflammation. Systemic complications, such as heart failure and diseases, can be fatal (4). Next, we report the case of a patient with Von Zumbusch's pustular psoriasis admitted to our service and admitted for clinical investigation. (5, 6)

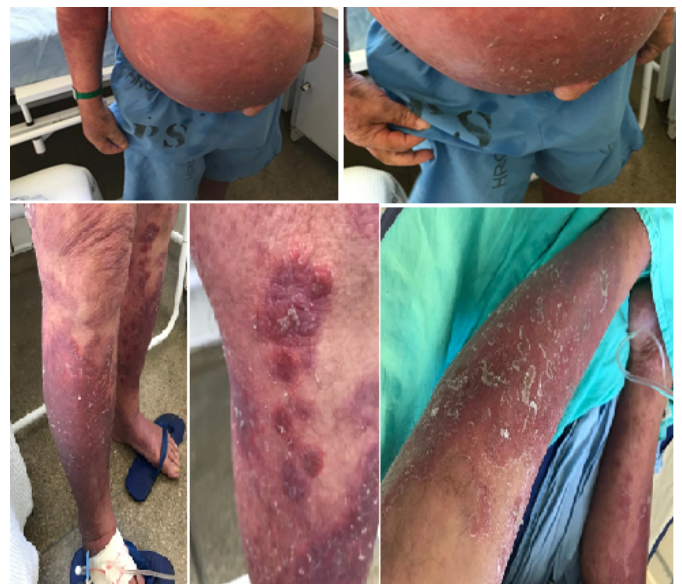## 2 | METHODS

Information obtained from a medical chart, photographic registers, histopathological examination and literacy review. The patient was admitted in the Ward of the medical clinico of the Regional Cacoal Hospital. The diagnosis was based on clinic findings and confirmed by skin biopsy. The patient went through blood cultures, routine laboratory tests and day monitoring of vitals. During admission the patient was treated with intravenous administration of fluids, analgesics, sunflower oil for skin moisture and hydrocortisone 1% ointment.

### 2.1 | Case Report

Male sex patient, 68 years old, bus collector, diabetic on metformin 850mg orally 12/12h and glibenclamide 5mg orally 12/12h, besides being asthmatic in irregular treatment with alenia without consulting with pneumatologist. Inhabitant of Rolim de Moura urban zone in the state of Rondônia, wooden household, no headliner, he denies having any contact to dust, consumption water comes from the streets, he denies smoking and drinking. The patient reports that approximately 4 years ago he started to show pruritic and desquamatory lesions only around his nape. Initially he looked for help on a farmacy without seeking medical assistance. After some years it evolved with lesion growth in a progressive way on craniocaudal axis, and also the appearance of other new lesions, what made him look for medical care that chose to admit him due to the presence of erythematous, infiltrating, pruritic plaques in members, torso and back, associated to a feeling of local "burnt". Once admitted, he got treated with crystallin penicilin and benzatin, he showed some

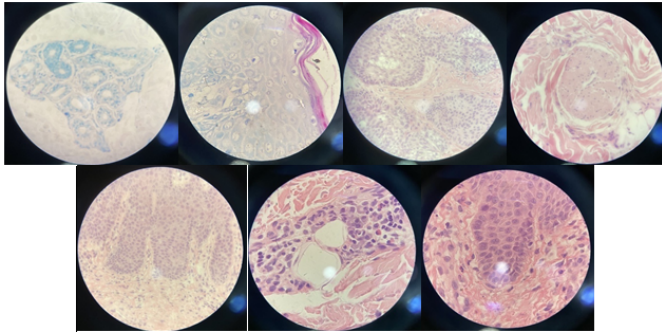
improvement regarding the described symptoms and Attenuation of the desquamation of the plaques, leaving only erythematous plaques. He was referred to the medical clinic sector of the Regional Hospital of Cacoal-RO for diagnostic elucidation. On admission, he denied any history of dermatological pathologies in first-degree relatives, but mentioned that a niece (his brother's daughter) was diagnosed with psoriasis one year ago. Mother died of neoplasia at 78 years of age and father died of a traffic accident. On physical examination, vital signs unchanged, he presented erythematous, largely non-descaling lesions on skin and focus of inflammatory process. Figure 1. Umbilical hernia of approximately 4 cm, not reducible, and edema in the lower limbs. Laboratory tests were negative for HIV, Syphilis, Hepatitis A, B and C. He was evaluated by the dermatology service that hypothesized pityriasis rubra pilaris, leprosy reaction, mycosis fungoides, and erythroderma. He started treatment with clobetasol ointment for 14 days and sunflower oil on the lesions, in addition to increased hydration.



**FIGURE 1:** *erythematous lesions with generalized thin and delicate scales and intense rederythema besides numerous previously ruptured pustules.*

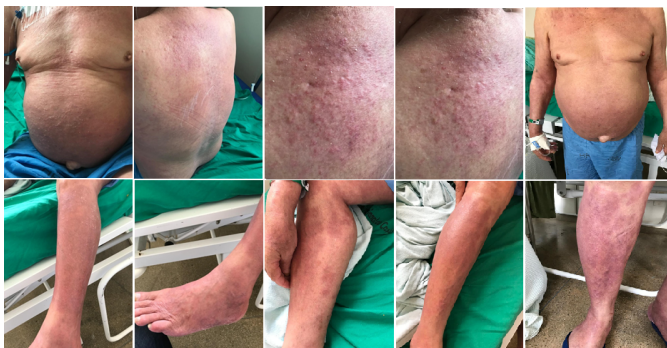A skin biopsy was performed with fragments from the leg, abdomen, and scalp Figure 2 confirming the hypothesis of pustular psoriasis.

After initial treatment with topical corticoid, the patient evolved with a decrease in erythema and areas



**FIGURE 2:** Sectionsshowing epidermis with regular acanthosis and hyperkeratosis with focuses ofparakeratosis and corneal microabscesses. Slight superficial perivascularlymphomononuclear inflammatory infiltrate. A negative acid-fast bacillusantibody (AFB) investigation and absence of malignancy.

of inflammation, and resolution of the desquamation processFigure 3 .



**FIGURE 3:** After corticotherapy, the patient evolved withresolution of the desquamation process of the lesions and reduction of theinflammatory and erythematous process.

Patient is discharged from hospital on acitretin 25 mg, 1 tablet a month, 1.5 pills in the second and third months, and 2 pills in the fourth month.

### 3 | DISCUSSION/CONCLUSION

Acute pustular psoriasis, also known as von Zumbusch psoriasis, whose immunopathology is still not fully understood. Currently suggested immunogenetic mechanisms for the disease are complex. The cytokines IL-36, IL-36 $\alpha$ , IL-36 $\beta$ , IL-36 $\gamma$  and the IL-36 receptor antagonist (IL-36Ra) are expressed

in a variety of cell types, including keratinocytes. During the inflammatory process there is release of chemokines that promote activation of neutrophils, macrophages, dendritic cells, and T cells, in addition to exacerbated IL-36 signaling. With mutation of the IL-36RN gene that in turn suppresses the pro-inflammatory action mediated by IL-36 $\alpha$ , IL-36 $\beta$ , and IL-36 $\gamma$  under physiological conditions.

With the aforementioned mutation, a decrease in anti-inflammatory activity occurs, which configures the dermatological and clinical prototype of the disease (7–9).

This form of the disease is usually triggered in patients with psoriasis vulgaris when they are subjected to aggravating factors, such as sunburn, use of lithium, anthralin, tar, chloroquine, beta blockers, NSAIDs, and especially abrupt discontinuation of corticotherapy, whether systemic or topical, as in the case of our patient who was irregularly using inhaled corticotherapy for asthma. Diagnosed with pustular psoriasis and corroborated by biopsy of the lesions, our patient showed partial resolution of the dermatological manifestations after the institution of corticotherapy. Generalized pustular psoriasis can often be persistent, making treatment difficult. Systemic retinoids have become the treatment of choice and over the years, other trial-based options for the various forms of psoriasis have been included (4). Systemic retinoids are the treatment of choice, however, other options include cyclosporine, etotrexate, colchicine, dapsone, and clofazimine[(1). Acitretin therapy can be performed as monotherapy or in combination with biologics and phototherapy, for example (3, 5, 6). Pustular psoriasis is associated with significant morbidity and, in some cases, mortality, especially in the absence of treatment (10). The patient is currently being followed up as an outpatient, with significant improvement of the lesions and in good general condition.

### REFERENCES

1. Jerez JT. Beatriz Alessi Rodrigues; Tatiana Jerez Jaime; Maria Lourdes Peris Barbo; Deborah Regina Cunha Simis. Psoríase de von Zumbusch. An Bras Dermatol. 2009;84(3):299–301.



2. Jerez JT, Beatriz Alessi Rodrigues; Tatiana Jerez Jaime; Maria Lourdes Peris Barbo; Deborah Regina Cunha Simis. Psoríase de von Zumbusch. *An Bras Dermatol*. 2009;84(3):299–301.
3. Sampaio S, Rivitti EA, *Dermatologia*; 2007.
4. Kerkhof PVD, Psoriasis. *Dermatology* New York: Mosby. 2003;p. 125–151.
5. FRITSCH P. Oral Retinoids in Dermatology. *International Journal of Dermatology*. 1981;20(5):314–329. Available from: <https://dx.doi.org/10.1111/j.1365-4362.1981.tb00814.x>.
6. Ettler K, Richards B. Acitretin therapy for palmoplantar pustulosis combined with UVA and topical 8-MOP. *International Journal of Dermatology*. 2001;40(8):541–542. Available from: <https://dx.doi.org/10.1046/j.1365-4362.2001.01094-3.x>.
7. Marrakchi S, Guigue P, Renshaw BR. Interleukin-36-receptor antagonist deficiency and generalized pustular psoriasis. *N Engl J Med*. 2011;365(7):620–628.
8. Onoufriadis A, Simpson MA, Pink AE. Mutations in IL36RN/IL1F5 are associated with the severe episodic inflammatory skin disease known as generalized pustular psoriasis. *Am J Hum Genet*. 2009;89(3):432–437.
9. Johnston A, Xing X, Wolterink L. IL-1 and IL-36 are dominant cytokines in generalized pustular psoriasis. *J Allergy Clin Immunol*. 2017;140(1):109–120.
10. Benjegerdes KE, Hyde K, Kivelevitch D, Mansouri B; 2016.

**How to cite this article:** Nazário de Oliveira A., R.B.F.M., S.M.C.M.P., R.M.S., C.R.S., R.O., K.F.M., L.C.F., W.F., E.C.O.C., M.G.M., G.E.A., R.C., F.J.J., K.B.M.M. **VON ZUMBUSCH PSORIASIS: A BRIEF REPORT**. *Advanced Research Journal of Medical and Clinical Sciences*. 2021;441–444. <https://doi.org/10.15520/ar-jmcs.v7i03.263>