

Case Report, Parosteal Osteoma of Ulna

Loli Anton¹, Astrawinata Guatama^{1*}, M. Andry Usman², Henry Yurianto², M. Ruksal Saleh³

1. Resident of Departement of Orthopaedic and Traumatology. Hasanuddin University, Makassar

2. Hip and Knee Consultant of Departement of Orthopaedic and Traumatology. Hasanuddin University, Makassar

3. Hand & Microsurgery Consultant of Departement of Orthopaedic and Traumatology. Hasanuddin University, Makassar

Received: 06th August | Accepted: 19th August 2020 | published: 20th August 2020

Abstract:

Background: Osteoma is a benign periosteal or endosteal tumour arising commonly in the craniofacial bones and mandible. Very few reports of extra cranial osteoma have been reported.

Methods: We present case of 45 years old woman with bone lesion in left ulna later diagnosed with osteoma. **Result:** Open biopsy with marginal resection was performed and the patient recover with no longer symptom or recurrence.

Conclusion: Parosteal osteoma of ulna may present in long bone as well in lower incidence, with equivalent succesful rate following standard treatment algorithm.

Keyword: Osteoma, parosteal, ulna, endosteal, extracranial, resection

Introduction:

Osteoma is benign tumor usually seen in flat bones. Osteoma usually presents as solitary tumor. It rarely presents as multiple lesion in Gardner's Syndrome. Osteoma involving long bones is very rare and review of literature showed only a few case reports. This is a case report of osteoma involving the shaft of the Ulna.

Case Report:

A 45-year-old woman presented with a large mass in the Postero-Medial aspect of distal left Forearm with limited motion of her left wrist. Radiographs revealed a well-defined, 6 cm × 3 cm, lobed mass in the one third distal shaft of the Left Ulna. Magnetic resonance imaging revealed that it had the same density as cortical bone. An open biopsy with marginal resection was performed to rule out malignant bone tumours, and parosteal osteoma

was diagnosed. Nine Months after the biopsy, the patient was asymptomatic.

Result:

After 9 month post-operative follow up, the wound was well healed with scar on the boundary stitches, functional result was good where patient can do daily activity with her left Forearm.

Brief Discussion:

Osteoma is a benign, slowly growing, asymptomatic, osteogenic neoplasm. Osteoma of long bone other than the skull and facial bones is an extremely rare. An extremely rare case of parosteal osteoma in ulna is reported. Radiographs of our patient revealed a well-defined, 6 cm × 3 cm, lobed mass in the one third distal shaft of the left ulna. Magnetic resonance imaging revealed that the tumor is isodens as cortical bone.

Histopathology study showed mature osteosit built hard lamellar bone and no malignant characteristic shown, thus parosteal osteoma was diagnosed. The most important and often most difficult lesion to differentiate from osteoma of long bone radiographically is parosteal osteosarcoma, which is a rare, low-grade surface osteosarcoma with the potential for dedifferentiation. The differential diagnosis of parosteal osteoma should include tumoural calcinosis, osteochondroma, myositis ossificans, parosteal osteosarcoma and parosteal chondrosarcoma. It is especially important to rule out a malignant bone tumour. Unlike conventional osteosarcoma, this type of tumour most commonly occurs in patients in the 3–5th decades of life. Although low-grade, the lesion can infiltrate the underlying cortex and extend into the medullary cavity; it also has a propensity to recur. Scintigraphy can help to differentiate osteosarcoma with parosteal osteoma.

Campannacci suggested that an osteoma should be treated with total excision biopsy. Partial resection of osteoma results in pain and necessitates an additional procedure to remove the remainder of the lesion. Proximal and distal wide margins are not indicated. Marginal excision can be performed in most of the cases. Therefore, we followed the principle of Campannacci and did a marginal excision.

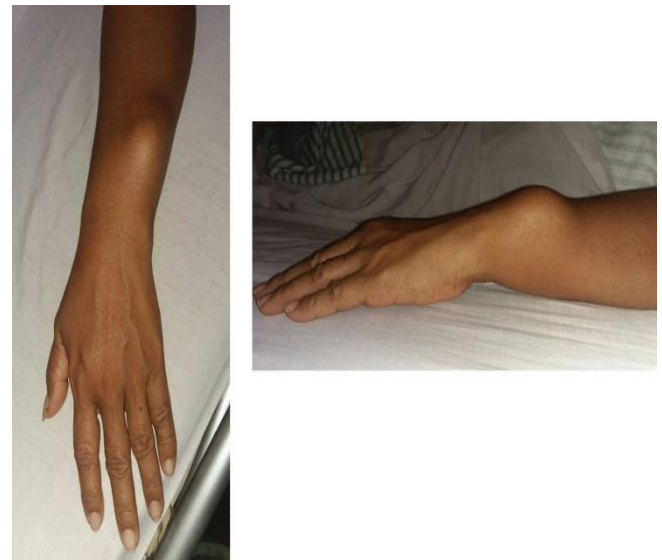

Image 2

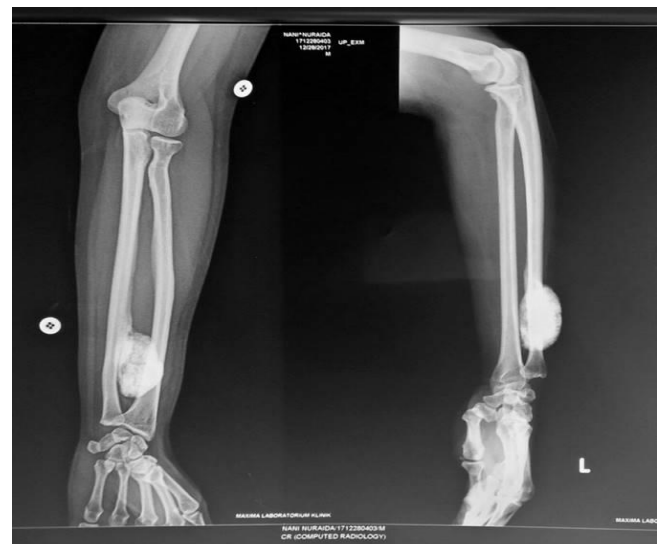

Image 3

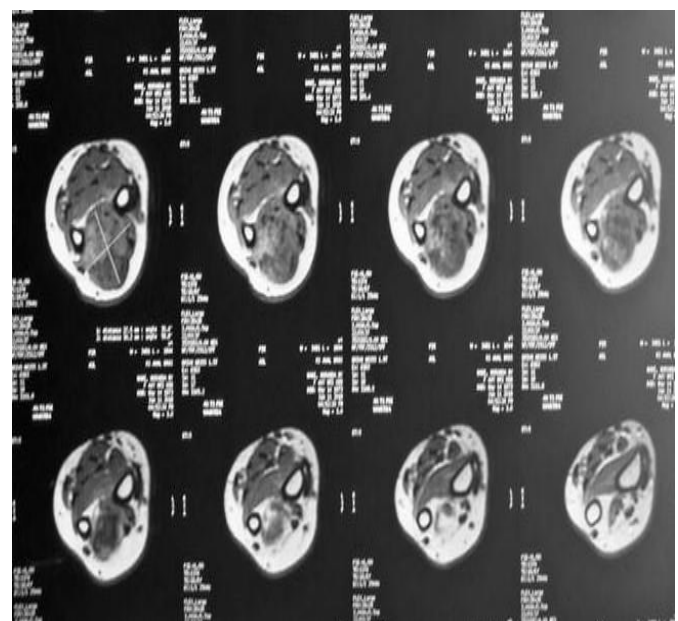


Image 4

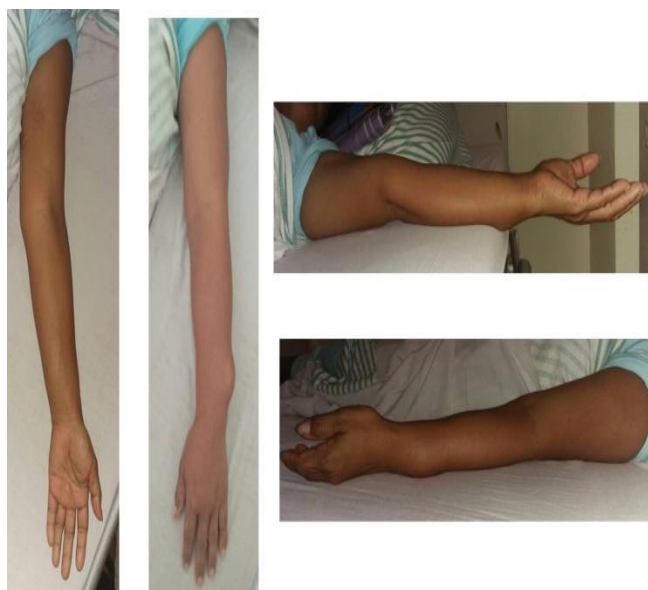

Image 1

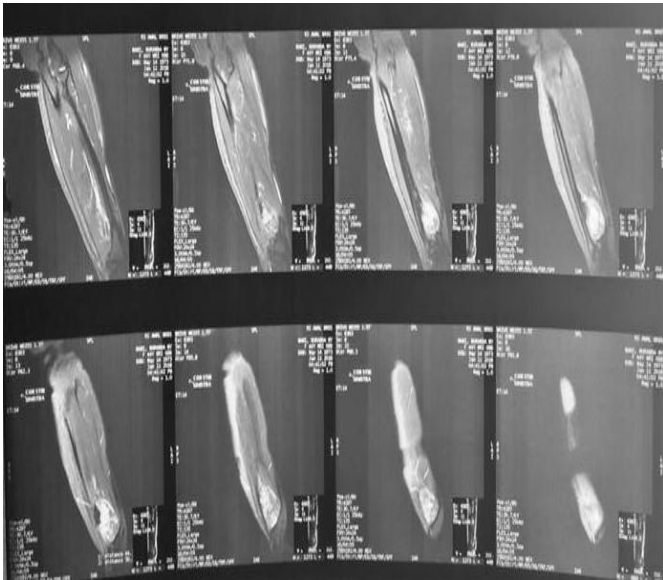


Image 5

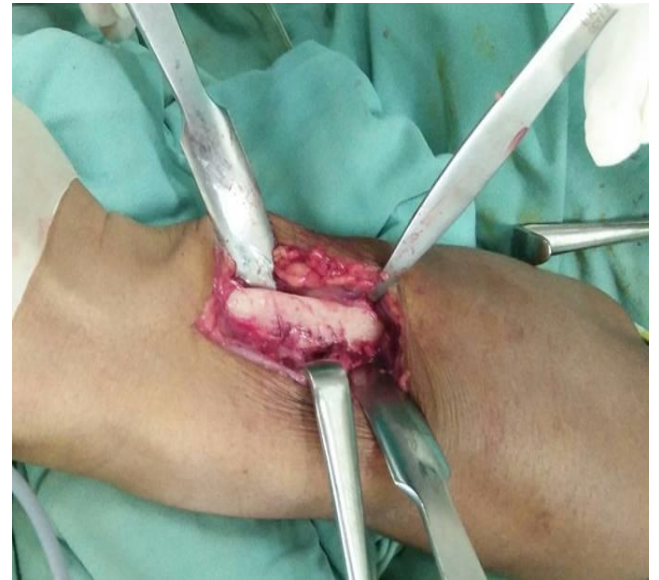

Image 8

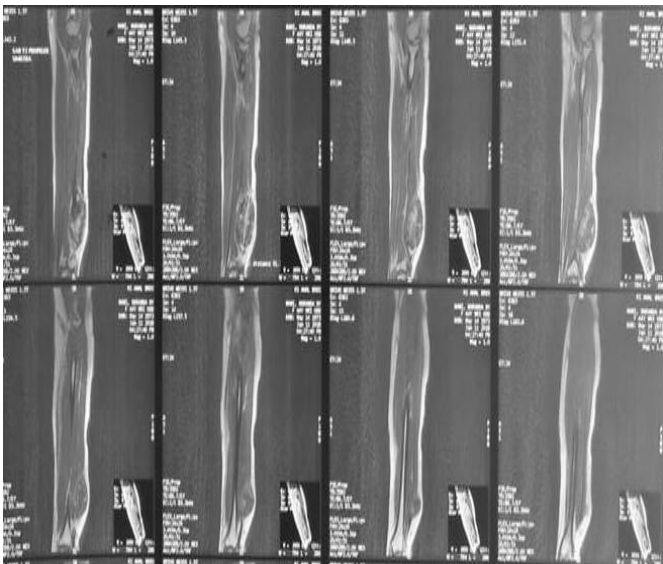


Image 6

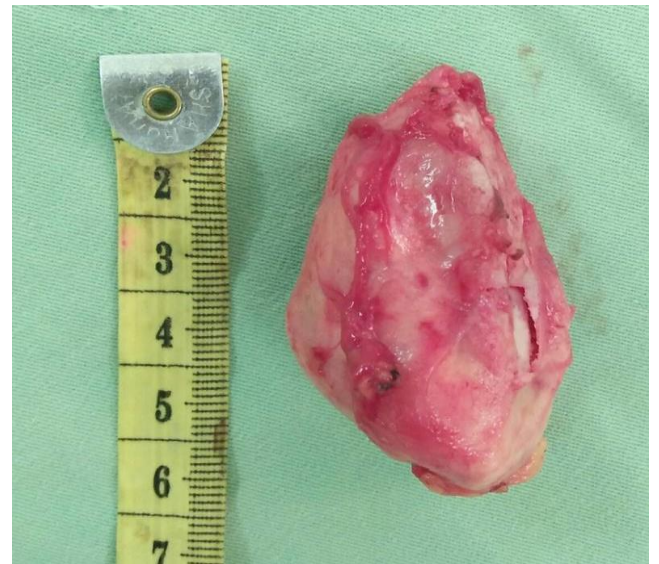

Image 9

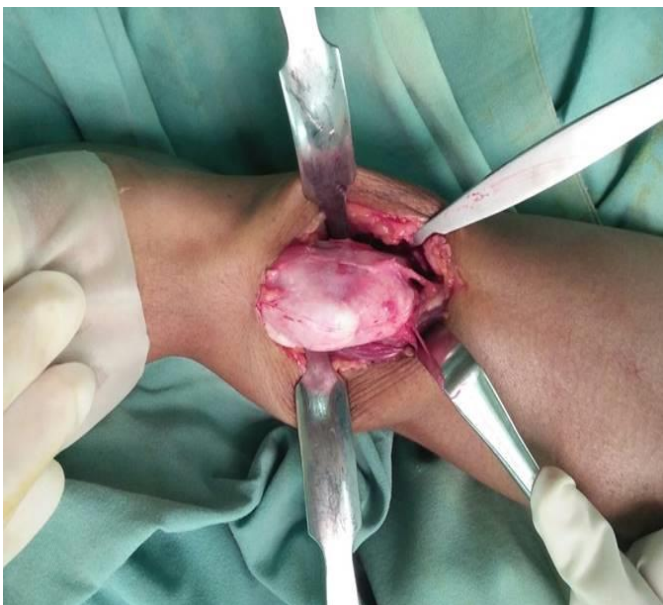

Image 7



Image 10

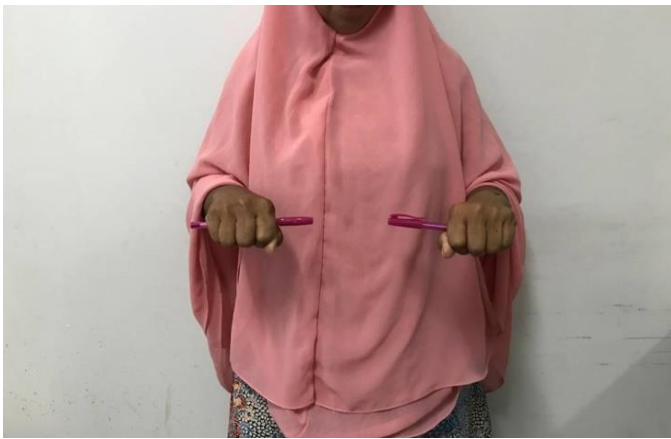

Image 11

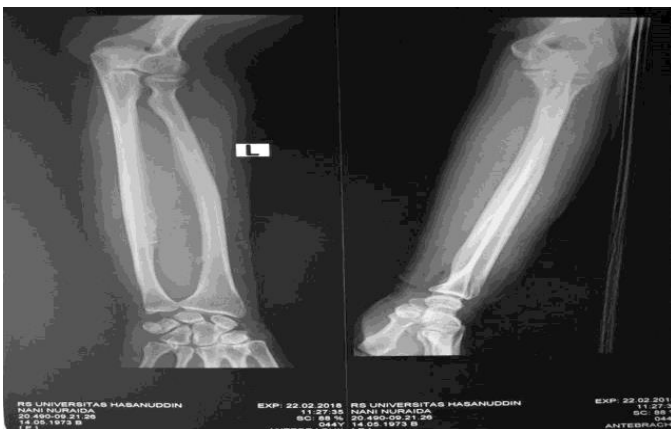

Image 12

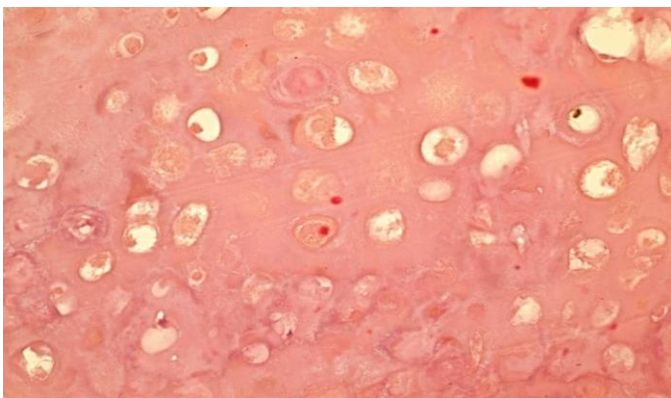


Image 13

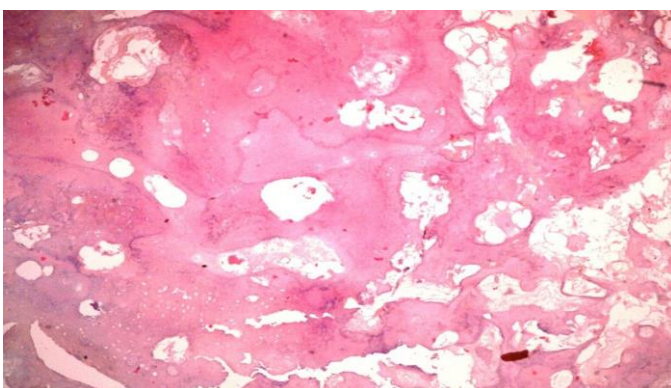


Image 14

Conclusion:

A rare case of parosteal osteoma of the ulna was described. Open biopsy is required to rule out a malignant bone tumour, even if parosteal osteoma is suspected based on the clinical course and imaging findings. Once the diagnosis of parosteal osteoma has been made, wide resection is no longer necessary because recurrence is rare and malignant transformation has never been reported. Therefore, only careful follow-up or marginal resection may be sufficient for this lesion.

References:

1. B. G. Hansford. P. Pytel. D. D. Moore. G. S. Stacy, Osteoma of long bone: an expanding spectrum of imaging findings, *Skeletal Radiology*, November 2014.
2. T. Inokuchi. T. Hitora. Y. Yamagami. H. Nishimura. T. Yamamoto, Parosteal Osteoma of the Clavicle, *Hindawi Publishing Corporation*, Vol August 2014.
3. H. Chikuda. T. Goto. T. Ishida. T. Iijima. K. Nakamura, Juxtacortical osteoma of the ulna, *J Orthop Sci* (2002) 7:721–723.
4. Soler Rich R, Martínez S, de Marcos JA, Salas A, Lluç P, Granados J. Parosteal osteoma of the iliac bone. *Skeletal Radiol*. 1998;27(3):161-163. doi:10.1007/s002560050357
5. Houghton MJ, Heiner JP, De Smet AA. Osteoma of the innominate bone with intraosseous and parosteal involvement. *Skeletal Radiol*. 1995;24(6):455-457. doi:10.1007/BF00941247
6. Meltzer CC, Scott WW Jr, McCarthy EF. Case report 698: Osteoma of the clavicle. *Skeletal Radiol*. 1991;20(7):555-557. doi:10.1007/BF00194259
7. Bertoni F, Unni KK, Beabout JW, Sim FH. Parosteal osteoma of bones other than of the skull and face. *Cancer*. 1995;75(10):2466-2473. doi:10.1002/1097-0142(19950515)75:10
8. O'Connell JX, Rosenthal DI, Mankin HJ, Rosenberg AE. Solitary osteoma of a long

Astrawinata Guatama et. al. / Parosteal Osteoma of Ulna
bone. A case report. J Bone Joint Surg Am.
1993 Dec; 75(12):1830-4.